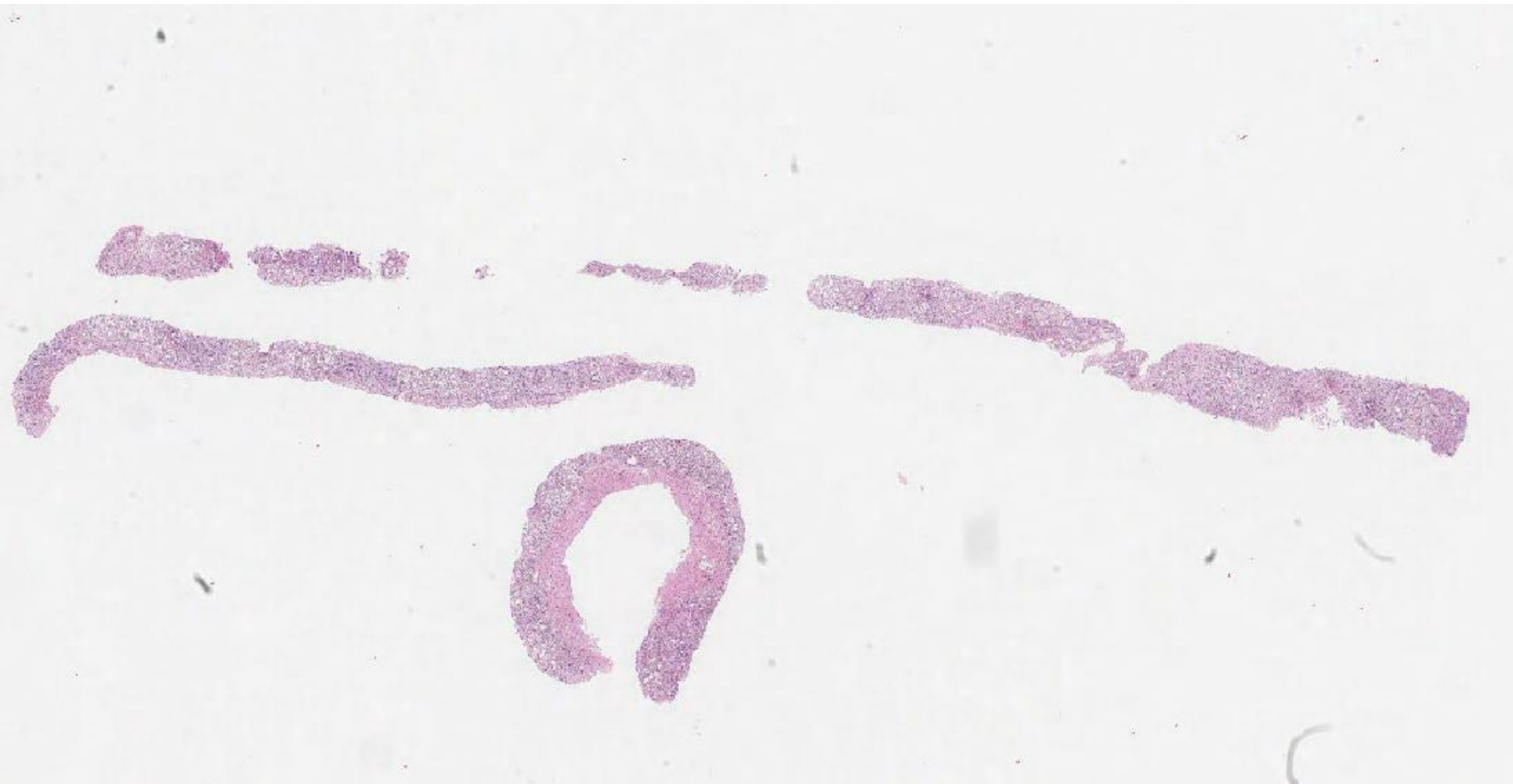

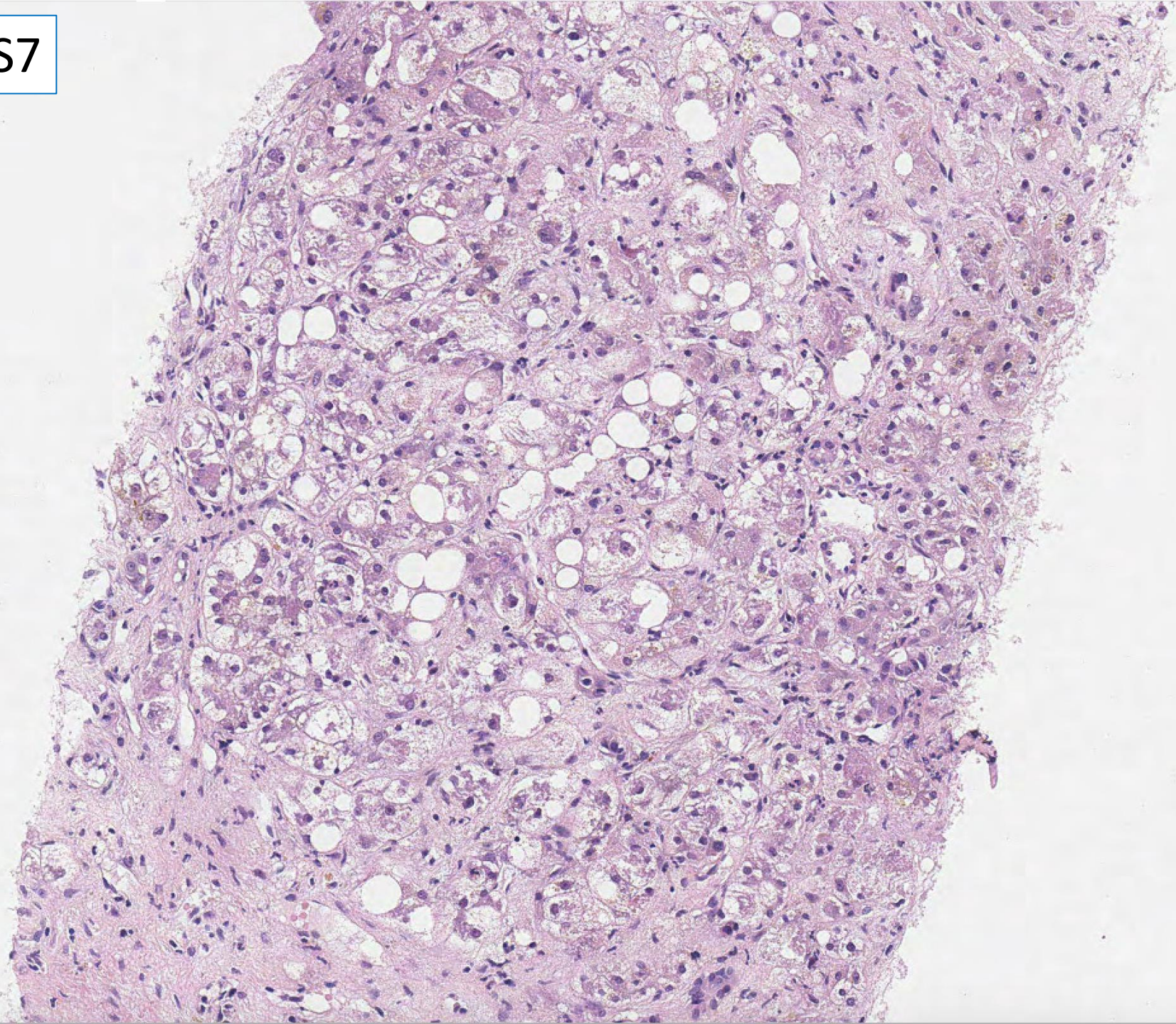
Case LS7 25 M

patient with subacute hepatic failure

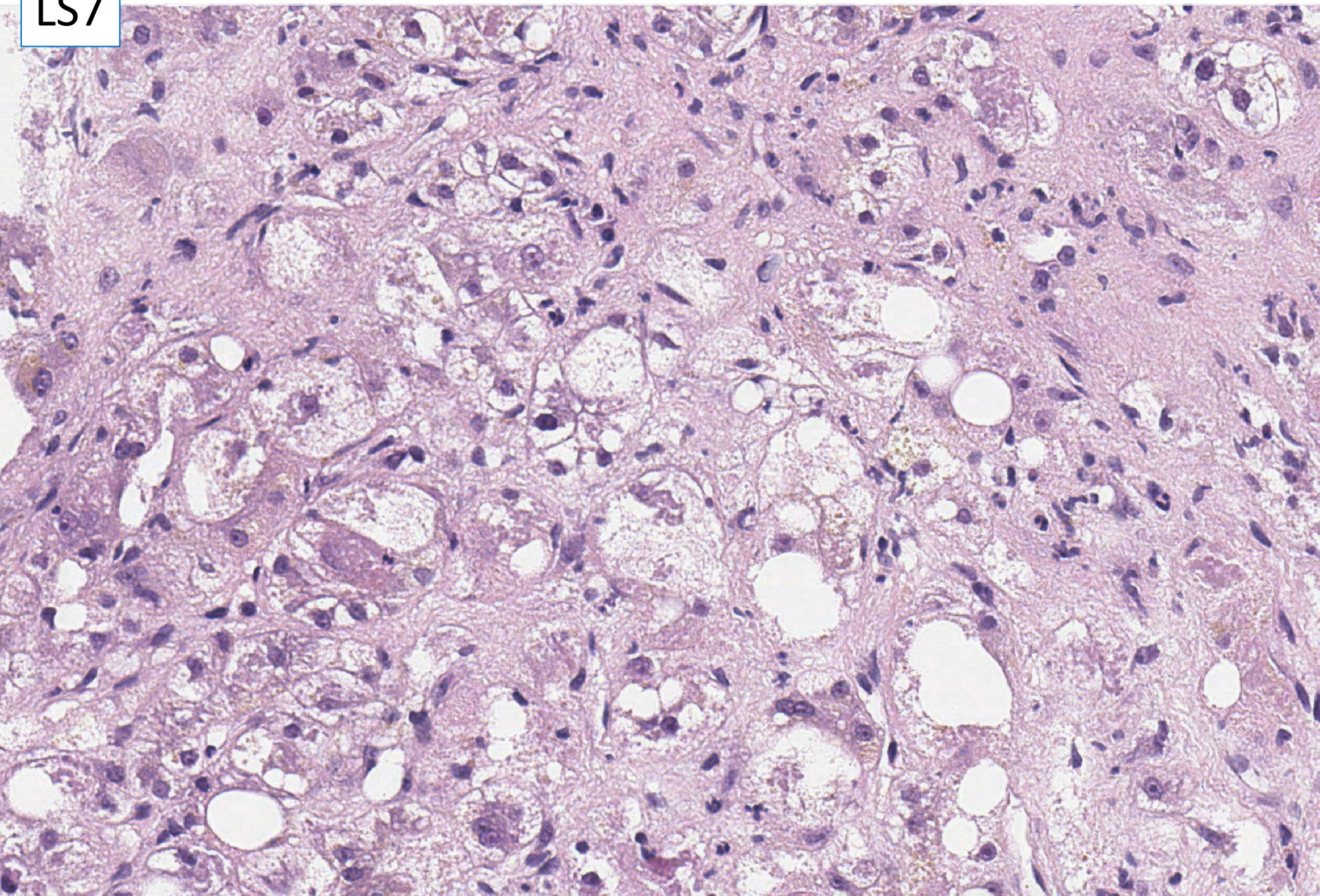
Also van Gieson, DPAS, reticulin



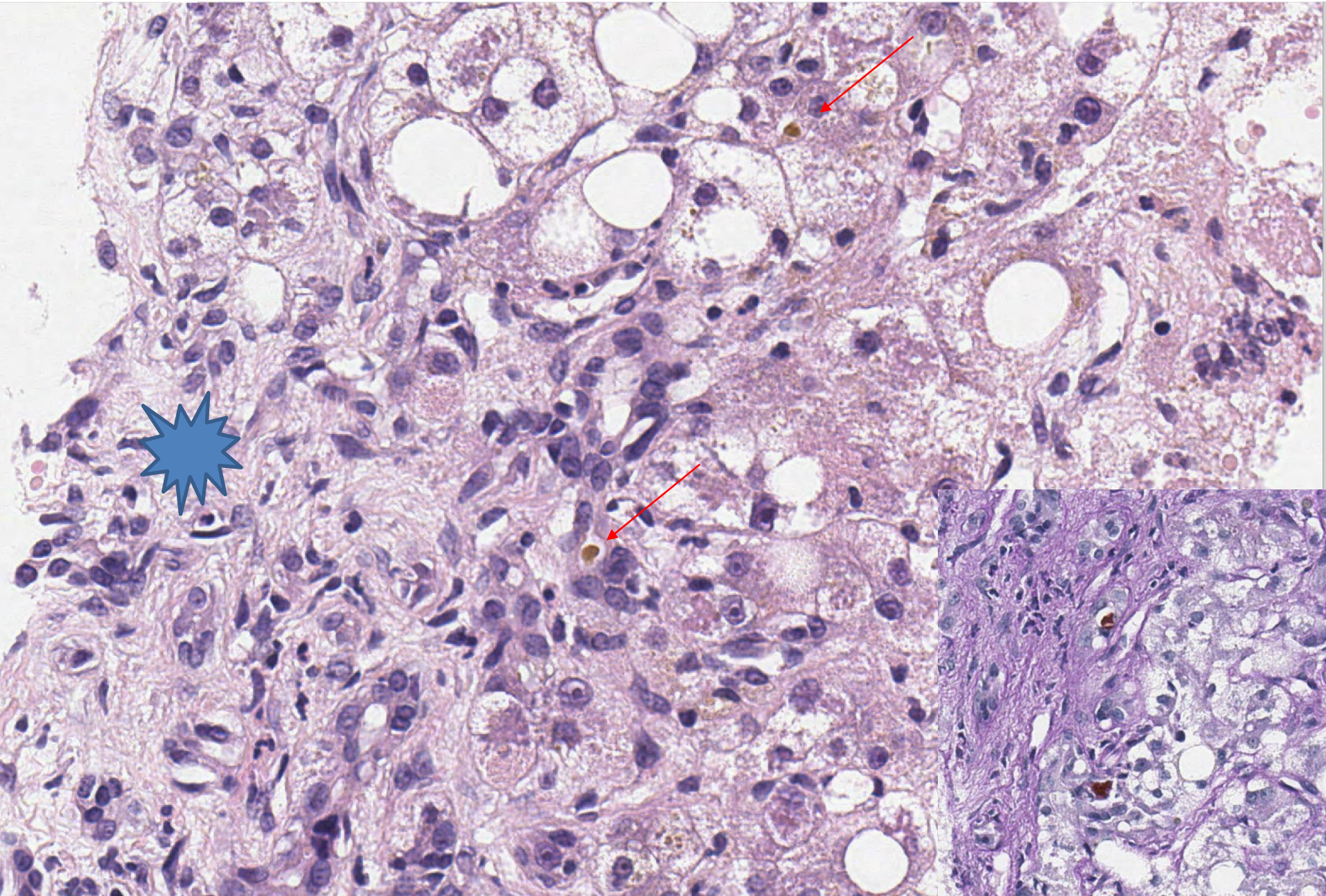
LS7



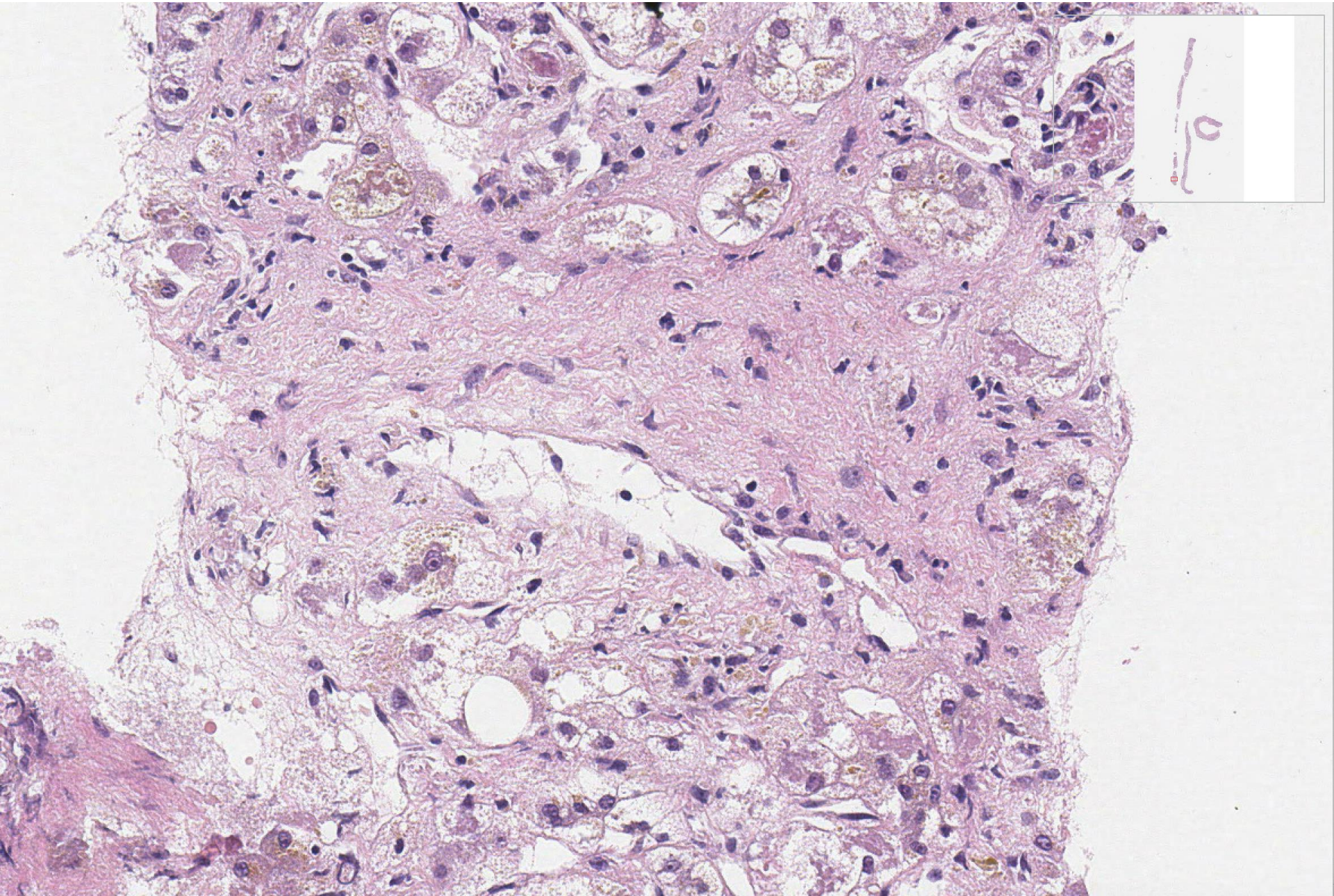
LS7



LS7

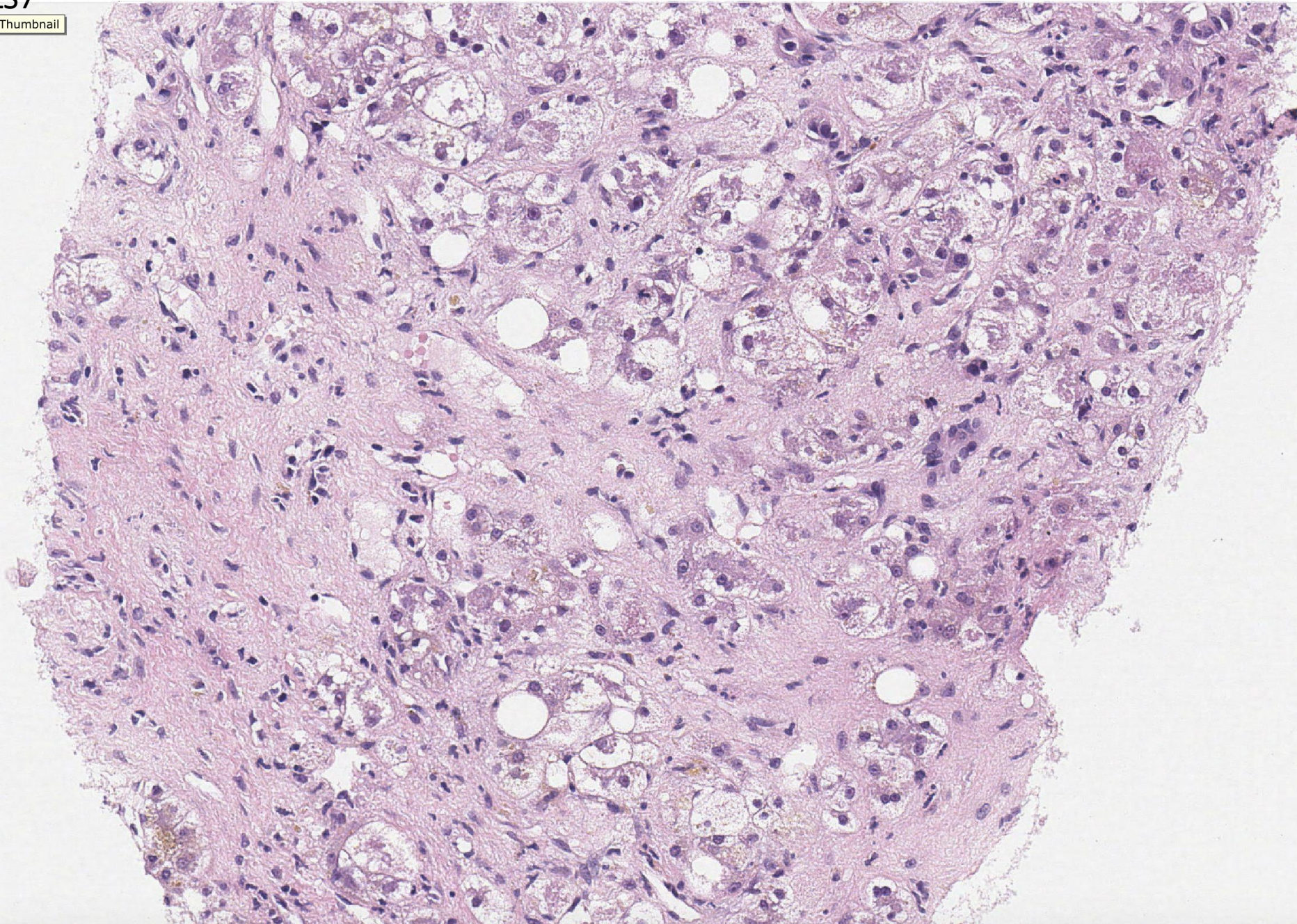


LS7

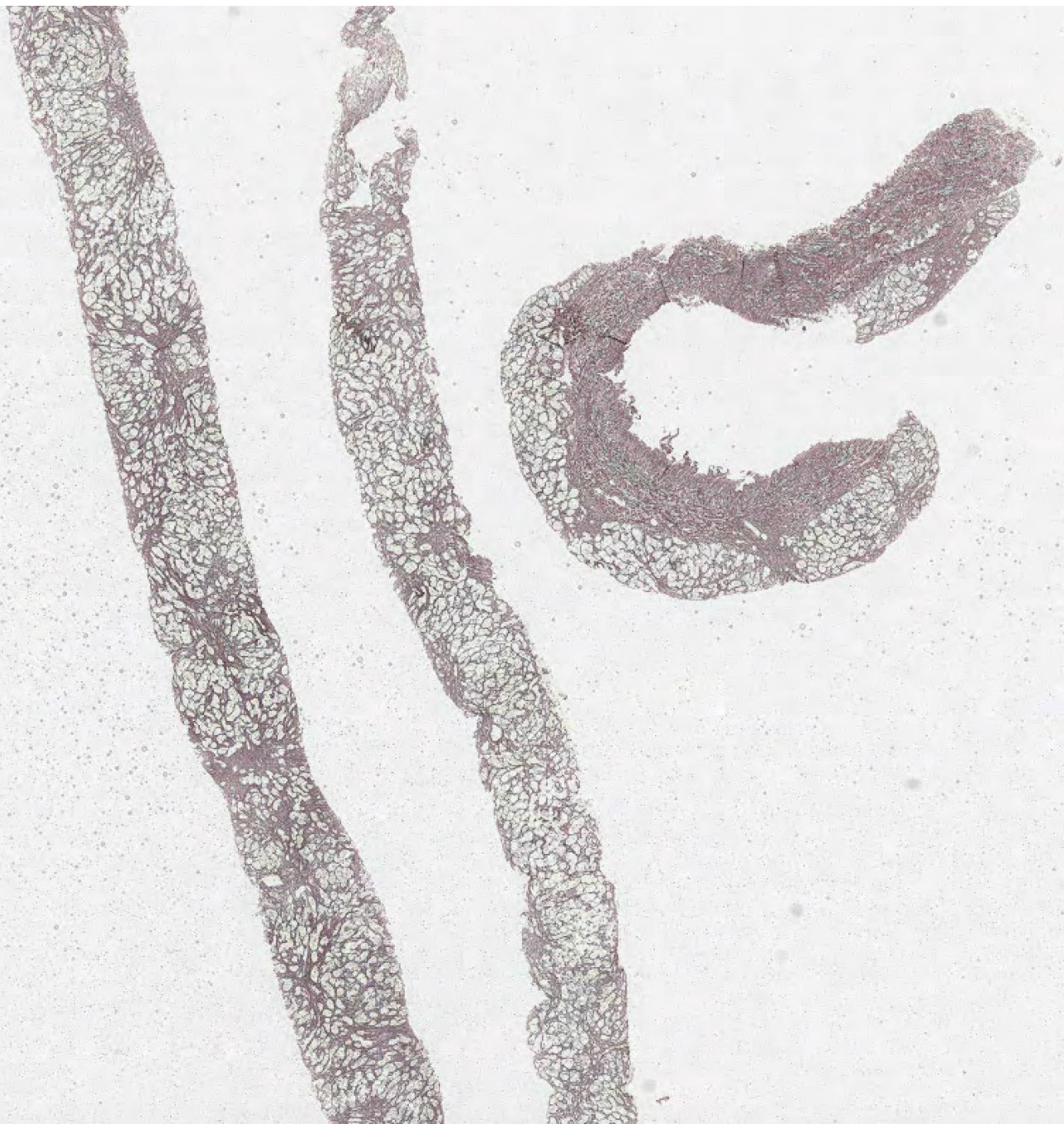

LS7

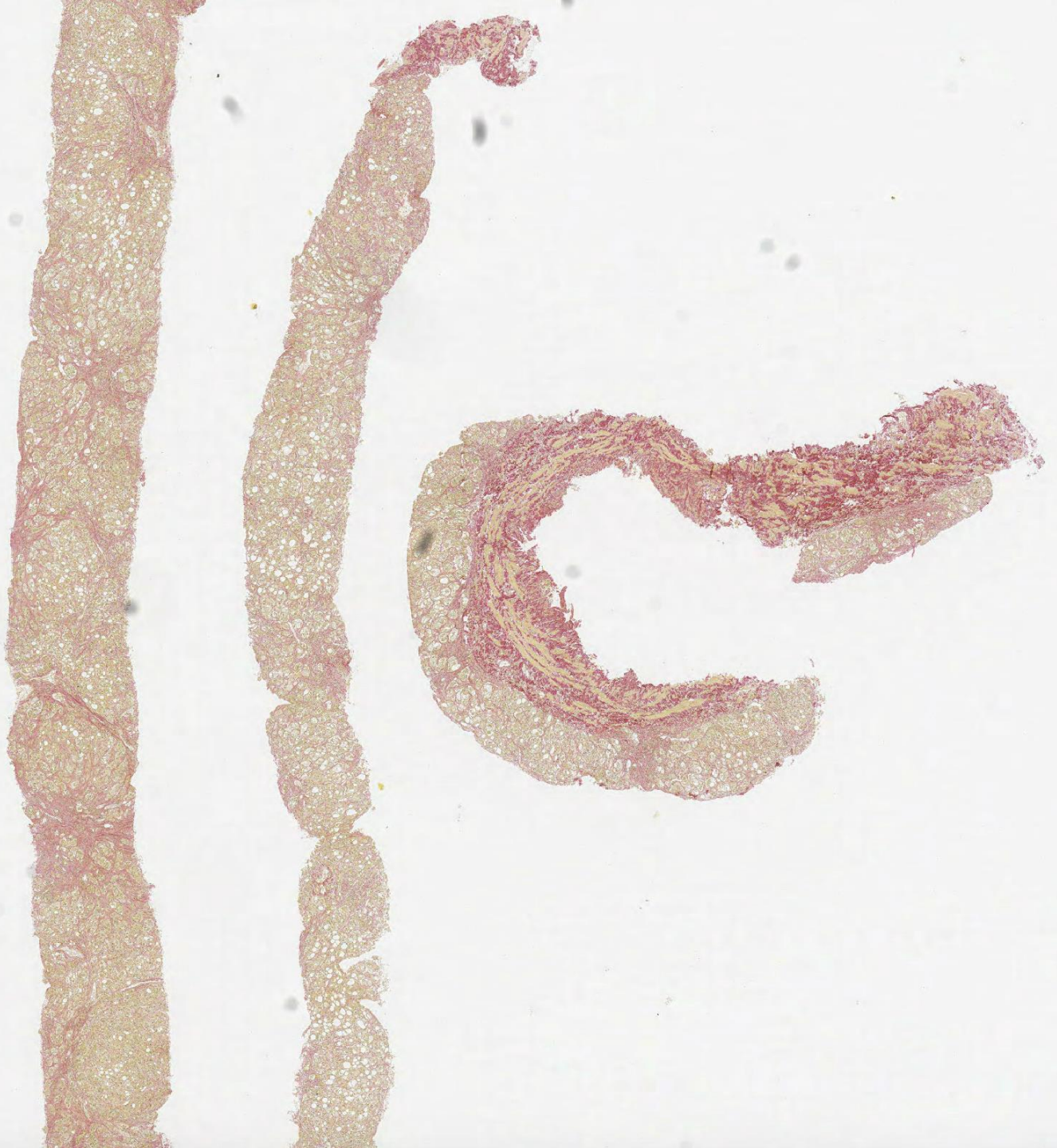
Thumbnail



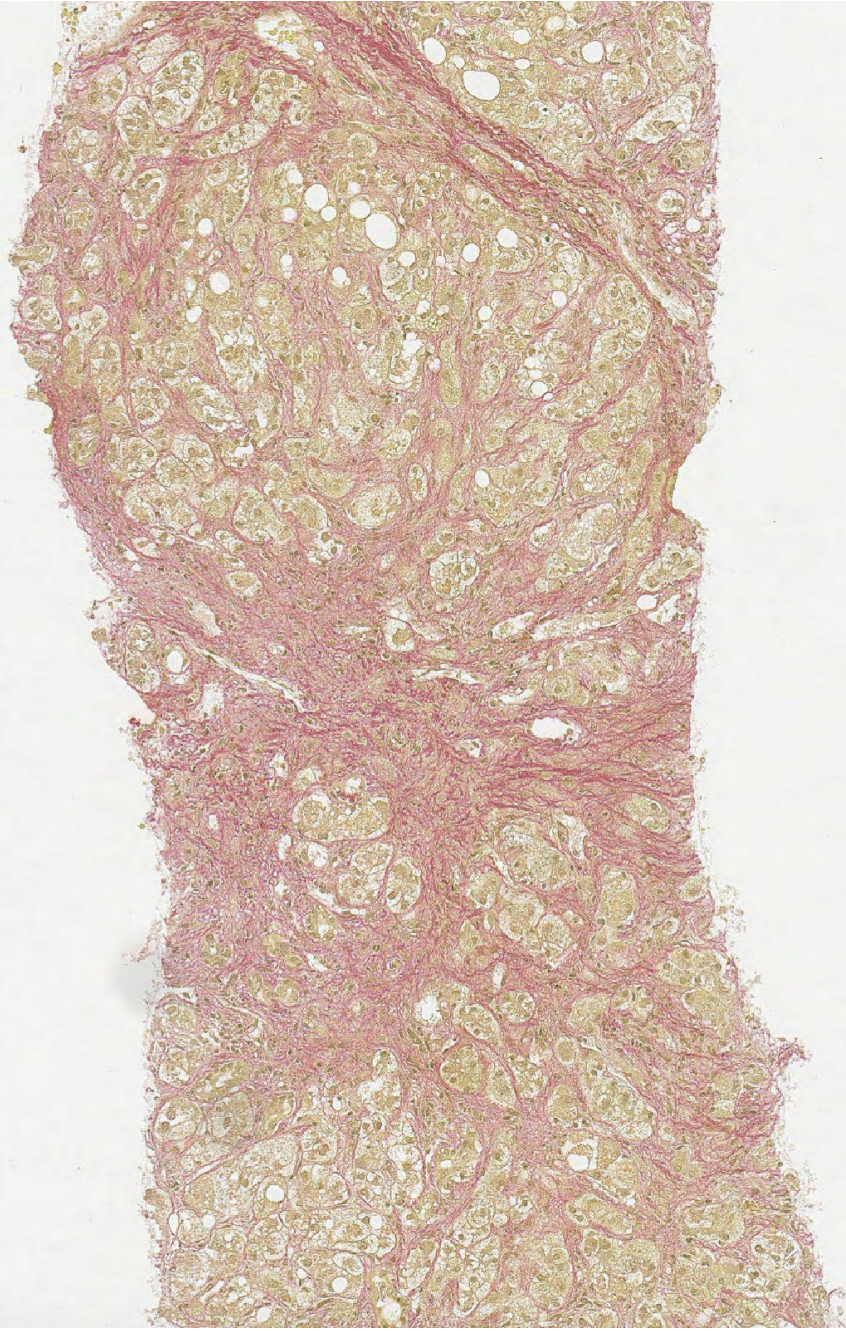
LS7
reticulin



LS7 van
Gieson



LS7



Case LS7 25 M

patient with subacute hepatic failure

Also van Gieson, DPAS, reticulin

A	Fatty change and fibrosis
B	Alcoholic foamy degeneration
C	Steatohepatitis, suggests alcohol related
D	Steatohepatitis, probably NASH
E	Subacute hepatitis with collapse